

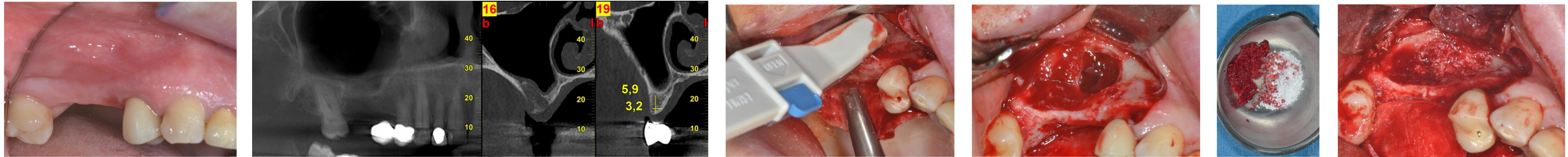


Objectives:

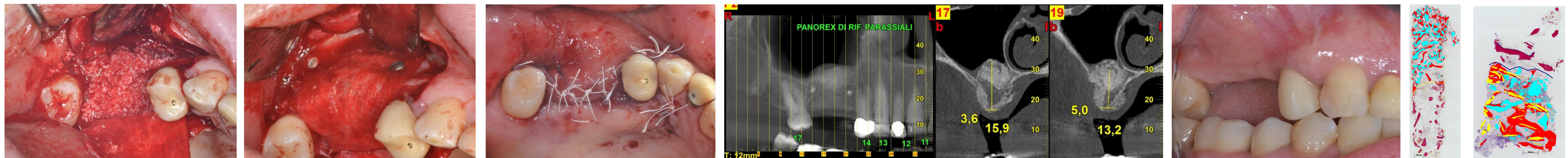
The aim of this study was to evaluate clinically, histologically and histomorphometrically a new porcine xenograft, characterized by the interconnecting macroscopic and microscopic porous structure of the graft material (88%-95% void space) that supports the formation and ingrowth of new bone, utilized to treat 3 different clinical cases requiring a bone graft: An horizontal guided bone regeneration (GBR) with simultaneous sinus lift (SL), a mandibular horizontal GBR, and a socket preservation.

Methods:

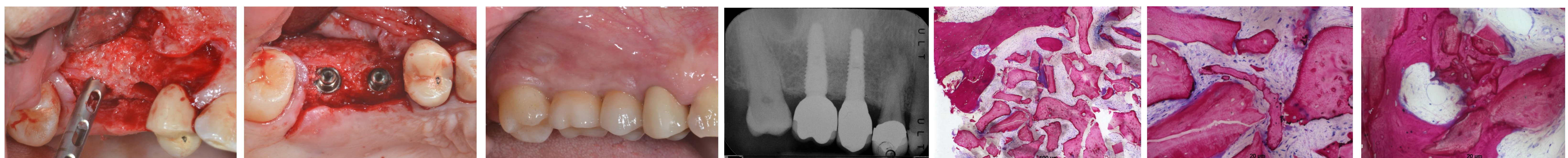
A porcine xenograft (Zcore, Osteogenics Biomedical) was used to treat 3 patients requiring the use of a bone graft: **Patient A** required an horizontal GBR with a simultaneous SL, and was treated with the application of a long lasting collagen membrane (Cytoplast RTM, Osteogenics Biomedical) with a resorption time of 26-38 weeks, a graft of 100% of xenograft inside the sinus, a 1:1 ratio mixture of xenograft and autogenous bone, harvested with a scraper from the lateral bone wall where the entrance to the maxillary sinus was performed, to correct the horizontal ridge defect. **Patient B** required a socket preservation after lower canine extraction. Only the xenograft filled the alveolar cavity that was closed with the application of a collagen fleece as a cap. **Patient C** required a mandibular horizontal GBR for the first molar implant rehabilitation, and was treated with the application of a long lasting collagen membrane (Cytoplast RTM, Osteogenics Biomedical) and a 1:1 ratio mixture of xenograft and autogenous bone, harvested locally with a scraper. Healing was uneventful for all the interventions and, after bone graft maturation, re-entry was scheduled after 8, 3 and 7 months for patient A, B and C respectively. Patient A received 2 implants in upper second premolar and first molar position. Two specimen were harvested during implant site preparations. Patient B and patient C received 1 implant each, and 1 specimen was taken during implant site preparation from each patient.



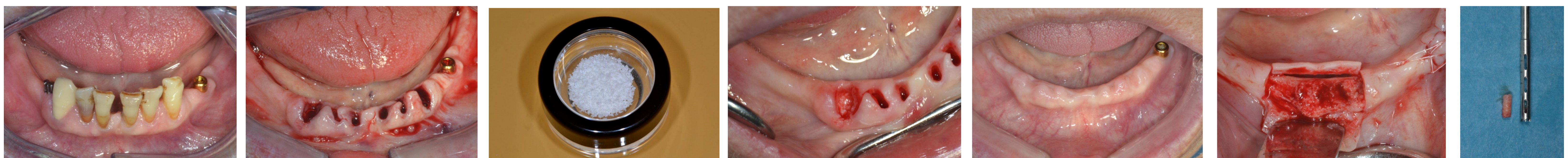
Case A: Horizontal ridge defect and sinus pneumatization in the upper right jaw. Autogenous particulate bone was harvested with a scraper during the sinus lift procedure and mixed to Zcore in a 1:1 ratio.



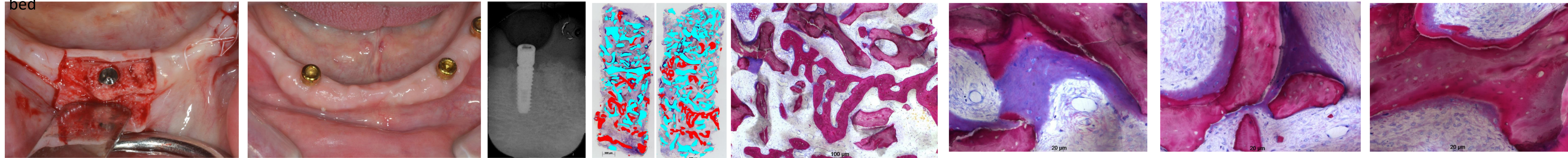
A Cytoplast RTM collagen membrane was stabilized with pins to cover the graft. CBCT scans revealed a vertical and horizontal bone augmentation. Healing was uneventful during all the period of graft maturation.



Two specimen were harvested during implant bed preparation for histologic and histomorphometric evaluation: the 1-year clinical and radiographical follow-up show an excellent result.



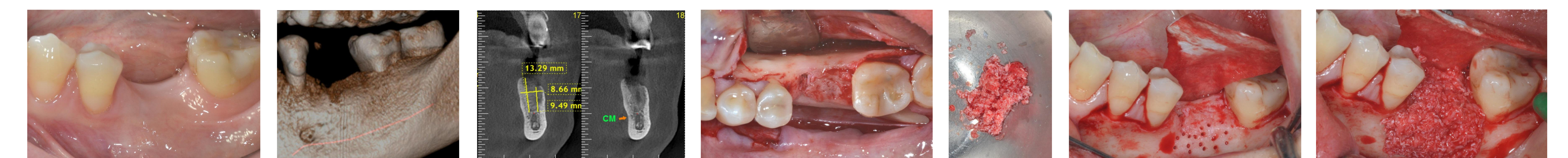Case B: Extraction of 6 anterior teeth affected by severe periodontitis, and socket preservation performed with Zcore particulate graft. After 3,5 months of healing, a bone specimen was harvested during implant bed



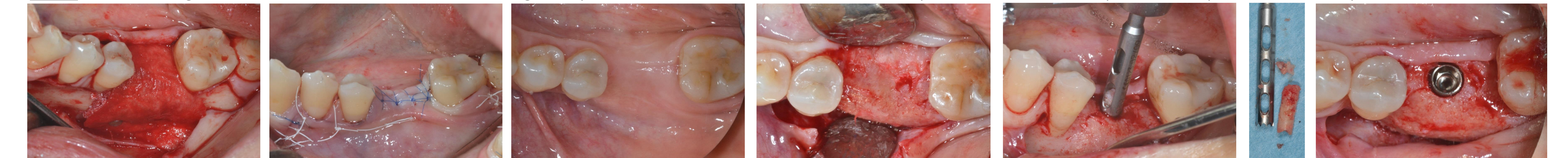preparation in the right canine site. The patient received a Locator-retained overdenture. Histologic sections show the formation of a trabecular bony network. Osteoid formation indicates ongoing bone synthesis.

Results:

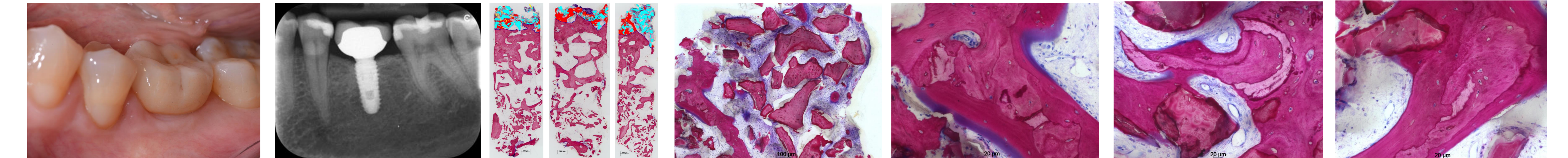
All implants healed uneventfully and received their prosthesis after a period of 4, 3 and 4 months for patient A, B, and C respectively. The specimen retrieved were defatted in Xylene, infiltrated, embedded and polymerized in Technovit 9100. Sections of 60 µm were stained with azure II and pararosaniline. Histological sections showed xenograft particles integrated in newly formed bone, active osteoblasts producing osteoid, demonstrating ongoing bone formation, and a bone marrow with well vascularized, uninfamed, loose connective tissue. Histomorphometric analysis was carried out on two sections per each specimen and the mean values are reported. For patient A, the first specimen investigated the regeneration inside the sinus and revealed a 60,2% of bone marrow/connective tissue and 39,8% of mineralized fraction (23,2% of ZCore, 16,6% of new bone mineral); the second specimen of patient A investigated the ridge regeneration and revealed a 58,1% of bone marrow/connective tissue and 41,9% of mineralized fraction (5,7% of avital autogenous bone, 22,0% of Zcore, 14,2% of new bone mineral). For patient B the specimen revealed a 61,4% of bone marrow/connective tissue and a 38,6% of mineralized fraction (27,8% of ZCore, 10,8% of new bone mineral). For patient C the specimen revealed a 52,1% of bone marrow/connective tissue and a 47,9% of mineralized fraction (1,1 of avital autogenous bone, 26,6% of ZCore, 20,2% of new bone mineral). **ACKNOWLEDGMENTS:** Histologic preparation/evaluation and histomorphometric analysis by Dr. Heiner Nagursky and Mrs. Annette Lindner, University of Freiburg, Germany



Case C: Horizontal ridge defect at the lower left first molar site. Autogenous particulate bone was harvested with a Safescraper Twist, mixed to Zcore particles, and placed over the recipient site to fill the defect.



A Cytoplast RTM membrane was stabilized with pins over the graft. Healing was uneventful and 8 months later, at re-entry, a specimen was taken for histologic analysis during the implant bed preparation.



Clinical and radiographic follow-up 1 year after prosthetic loading. Histologic sections show, in the augmented area, Zcore particles and avital autogenous bone chips that are embedded in newly formed bone.

Conclusions:

The use of a new porcine xenograft, characterized by an hyper porosity of cancellous matrix and intra-particle space, with a reduced bulk density of the graft, allowed greater empty space for new bone growth. The values of histomorphometric analysis highlight a very good new bone formation for all the interventions, considering the times of bone graft maturation not really very long. Clinically, at re-entry for implant insertion, the bone graft appeared compact and well integrated to the native adjacent bone, and the graft particles were not so evident. All the implants became osseointegrated, and the 1-year follow-up didn't evidence any problem. Since this report is based on few clinical cases, a long-term prospective and controlled clinical study is needed to confirm the good results obtained in this study.